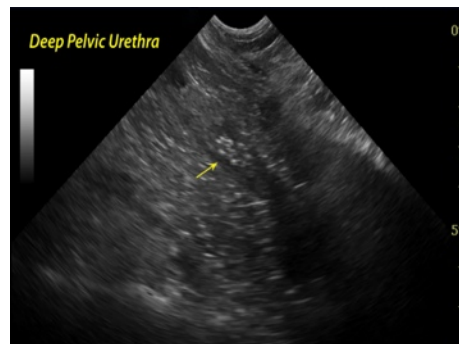


"You are receiving this monthly SonoPath.com newsletter on hot sonographic pathology subjects that we see every day owing to your relationship with a trusted clinical sonography service. This service has a working relationship with SonoPath.com and sees value in enhancing diagnostic efficiency in veterinary medicine."

Brought to by:



FEBRUARY 2012
TRANSITIONAL CELL CARCINOMA – 4 PAGES



Many cases of TCC go undiagnosed and mistreated as urinary tract infections until an advanced stage has been achieved increasing the unlikelihood of treatment success. In dogs, TCC represents 90-95% of bladder tumors with the remainder represented by squamous cell carcinomas, adenocarcinomas, papilomas, leiomyosarcoma, fibrosarcoma, hemangiosarcoma, and rhabdomyosarcoma. In cats urinary tumors are rare with lymphosarcoma and nephroblastoma being the primary players.

Typical **clinical signs** of TCC include

Mean age of diagnosis 11 years

Female:male ratio 1.7:1

Hematuria, stranguria, pollakuria, lethargy, weight loss, bone pain or organ failure due to metastasis.

Scottish Terriers, Shetland Sheepdogs, West Highland Terriers, Airdale Terriers and Beagles are over-represented.

Obesity
 Insecticide exposure
 History of Cytoxan/acrolein induced hemorrhagic cystitis

Withrow and MacEwen cite increased risk factor for Scottish Terriers and herbicides alone, herbicides and insecticides, but not insecticides alone—

Diagnostics: Urine sediment analysis may reveal neoplastic cells in 30% of cases, yet interpretation must be scrupulous as reactive cells have similar morphology. Ultrasound diagnostics, where available, provides prompt visualization as well as early detection by imaging minute irregularities in the bladder wall down to 2 mm. Ultrasound can also evaluate regional lymph nodes and other organs for evidence of metastasis. It can also evaluate the kidneys and ureter for evidence of impingement and back-pressure from tumours located in the trigone area. Early detection in the future may be provided by the veterinary bladder tumor antigen test (V-BTA, Bion Diagnostics) with 90% specificity and 78% sensitivity from a study of 65 dogs. False positives occurred with hematuria, proteinuria, and glucosuria.

The VBTA is best used as a screening test but not as a diagnostic test. A negative test suggests that TCC is not likely present but a positive test indicates that more testing and a cytopathological or histopathological test is warranted. This test has good sensitivity but only reasonable specificity. However, the negative predictive value is almost 100%. The most appropriate use of this test may be as a screening test to rule out TCC in geriatric dogs. The second (BTA Stat) and third (Bard Trak) generation tests should not be used in dogs as these give false negative results.

Treatment and prognosis: Up to 80% of the urinary bladder can be surgically resected without long-term compromise provided that the trigone is not involved. However, TCC in dogs often involves the trigone area. TCC in dogs is metastatic, and up to 40% of dogs have metastatic disease at the time of diagnosis (17% to lungs). A 70- dog study performed at Purdue university revealed that 25 dogs were treated with surgical debulking and medical therapy (chemotherapy and/or piroxicam) presented a median life span of 272 days. Cases of biopsy only with medical therapy (42 dogs) presented a median life span of 195 days with 150 days for those cases of medical therapy only (36 dogs).

Surgical options include partial cystectomy, total cystectomy, ureterocolonic anastomosis, or placement of permanent cystostomy catheter. Complete staging including 3-view thoracic radiographs and abdominal ultrasound should be performed prior to surgical intervention. Screening spinal radiographs should be performed to evaluate lumbar vertebrae.

Survival times range from months to >48 months depending on staging criteria and procedure performed. This survival rate of “non-resectable” trigonal/urethral TCCs has been redefined recently with the development of **ultrasound guided endoscopic laser ablation (UGELAB) of non-resectable bladder tumors**. This procedure was founded in 2003 by Dr. Dean Cerf (Ridgewood veterinary Hospital) and Dr. Eric Lindquist (NJ Mobile Associates & SonoPath.com). **Endoscopic and ultrasound videos of the UGELAB procedure may be viewed at www.SonoPath.com**. UGELAB has shown significant success and can be repeated as progression occurs. This procedure avoids seeding by keeping the exfoliating cells within the bladder and is an excellent method of obtaining clean samples given that this tumor is notorious for its “trailing” ability along needle passages (FNA, USG Bx). Personal observation has noted that strongly mineralized tumors benefit most from laser ablation given that tumor reduction from chemotherapy does not, logically, tend to be as effective in these cases. Range of survival time for our UGELAB patients (>60 patients) varies by tumor position and ureteral involvement but is from 8 days to 6 years with median survival above 360 days even after other therapies have been attempted.

Complete surgical excision of TCC usually is not possible due to trigone location, tumour size and the presence of multifocal TCC. A series of 67 dogs with TCC included 2 dogs with tumour-free

margins, but one of these dogs had a relapse 8 months later, and the other developed metastatic disease. Radiation therapy alone does not appear to be effective. Controversy exists regarding the benefit of surgical debulking.

Chemotherapy seems to be the mainstay of treatment as radiation therapy leads to difficulties with bladder fibrosis. Henry et al at ACVIM 2001 presented the following suggested therapeutics: Cisplatin (mean survival time 132 days), carboplatin (mst 180d), doxorubicin + Cyclophosphamide (mst 259d), gemcitabine, taxol, 5-fluorouridine and mitoxantrone (response rate 35%) have shown to be effective. Piroxicam (mst 210d) (Feldene) (0.3mg/kg sid) has antineoplastic activity as a nonselective cyclooxygenase inhibitor retarding its procancer effects. Of the NSAIDS, piroxicam is the most notably nephrotoxic. To prevent and treat gastric ulceration, Cytotec (misoprostol, a prostaglandin E analog) should be employed. Treatment limiting renal failure and gastritis/ulcerative side effects are its primary drawbacks. A more recent study of 18 patients at Purdue presented at ACVIM 2001 revealed a remission rate of 18%. 6 had partial remission (>50% reduction in tumor volume), 9 stable disease (<50% change in tumor volume), and 3 with progressive disease (>50% increase in tumor volume +/- new lesions). Piroxicam shows greater therapeutic use when coupled with other chemotherapeutics. Henry et al, 2003 coupled mitoxantrone with piroxicam, and found response in 35.4 % of patients with a subjective improvement in 75% of the cases. Median survival time was 291 days. The most recent study coupling piroxicam with carboplatin did not show increased life expectancy when compared to piroxicam alone. A recent study showed promising early results for intravesical Mitomycin C. The current recommendation (Ettinger Textbook of Veterinary Internal Medicine 2010) is single agent piroxicam or a combination of piroxicam and mitoxantrone. Chemotherapeutic suggestions may change based on future studies; consultation with a veterinary oncologist is recommended for these situations.

Multimodal therapy including chemotherapy and radiation may extend disease free interval.

Metastasis rates in the Purdue study revealed 16% nodal, and 14% distant with 49% distant at the time of death if the patients were not euthanized due to urinary obstruction. Distant met sites included lung (28%), iliac nodes (26%), liver (18%), kidney (4%), spleen (4%), other nodes (4%), and uterus (4%). 20% of TCC's present metastasis at time of diagnosis.

Urethral obstruction may be treated by indwelling catheter, intermittent catheterization, or tube cystotomy. Frequent treatment for uti is usually necessary. Gastric protection during piroxicam therapy can be provided by pepcid, carafate, or misoprostol as necessary to control appetite, hematemesis, and melena. Dogs with TCC may have recurrent or chronic urinary tract infections, and so the clinician should remain vigilant for this complicating problem.

Ureteral and urethral obstruction may be relieved by stent placement, as can ureteral obstruction. The Interventional Radiology service at the Animal Medical Center may be further consulted on this matter.

Patients with TCC (especially those receiving piroxicam, other NSAIDS or chemotherapy) should be carefully monitored with regard to infection and renal function. Infections should be controlled with antibiotics, although cystocentesis is not recommended due to possible tumour seeding. Rather a catheterized sample is recommended or an empirical antibiotic choice made. Renal function should be very carefully monitored due to the fact that these are often older dogs (with possible underlying renal disease) that have a high risk of urethral or ureteral blockage due to the tumour. Serial urinalysis and chemistry panel monitoring should occur, and follow-up ultrasounds to evaluate the kidneys and proximal urethra are highly recommended.

T

This summary represents a collection of data including presented at ACVIM 2001-2011 as well as personal observations. ACVIM 2008 Proceedings; Withrow and MacEwen's Small Animal Clinical Oncology 2007; Ettinger's Textbook of Veterinary Internal Medicine 2010, research undergoing at SonoPath.com.

Eric Lindquist DMV (Italy), DABVP K9 & Feline Practice


Cert. IVUSS

Director NJ Mobile Associates, Founder SonoPath.com

COME VISIT US AND LIKE US ON FACEBOOK!

"Make every obstacle an opportunity." Lance Armstrong

This Communication has Been Fueled By



SonoPath LLC. 31 Maple Tree Ln. Sparta, NJ 07871 USA

Via Costagrande 46, MontePorzio Catone (Roma) 00040 Italy **Tel: 800 838-4268**

For Case Studies & More Hot Topics In Veterinary Medicine For The GP & Clinical Sonographer Alike, Visit

www.SonoPath.com